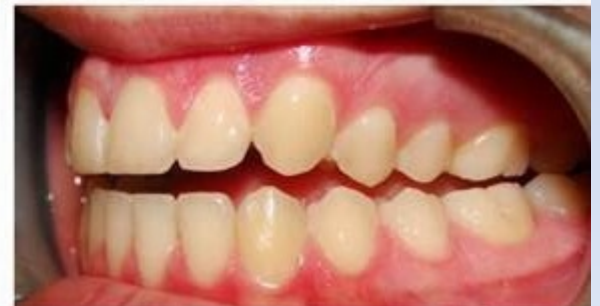
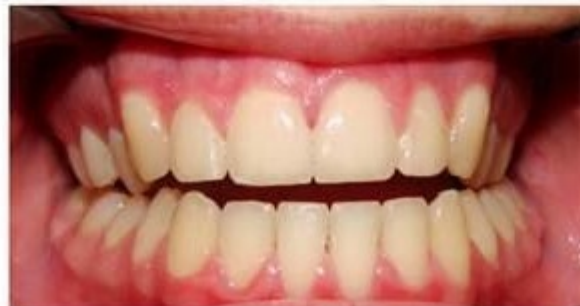
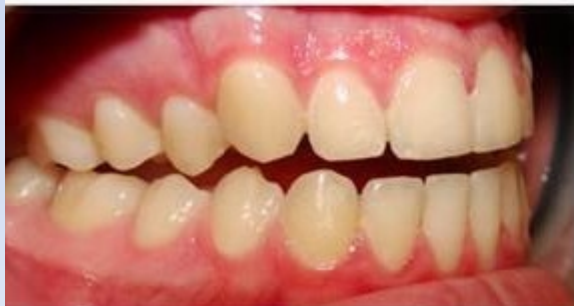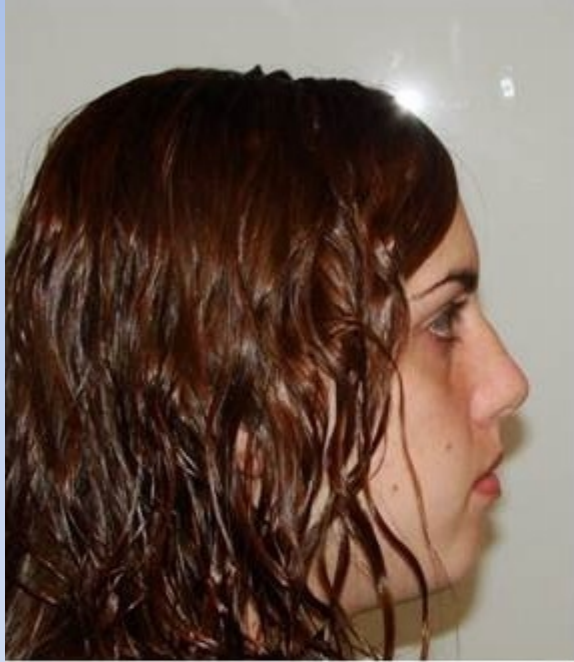“The Intruder”

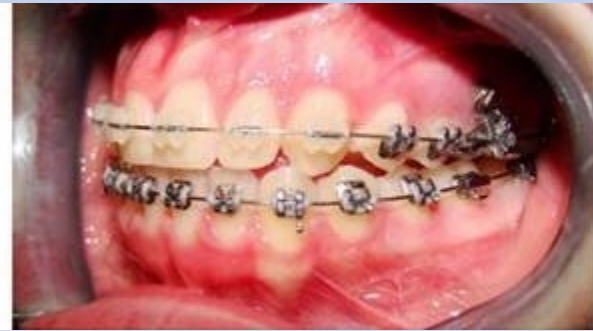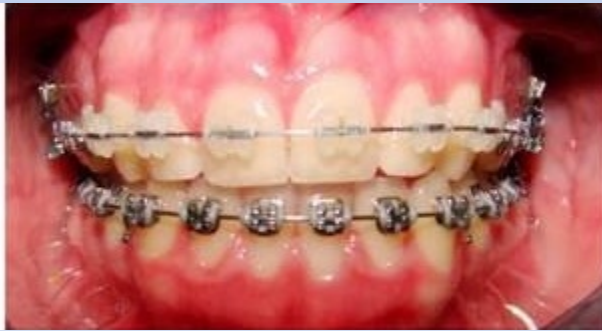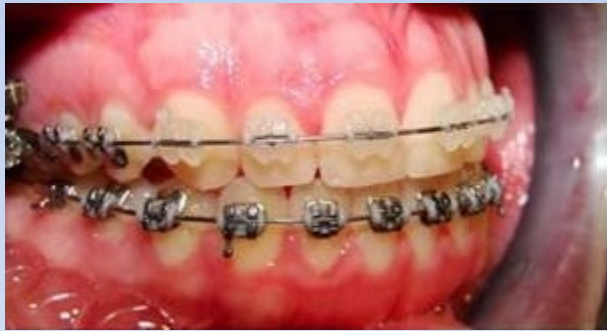The Simple Way to Close Open Bites

Vertical Skeletal Excess

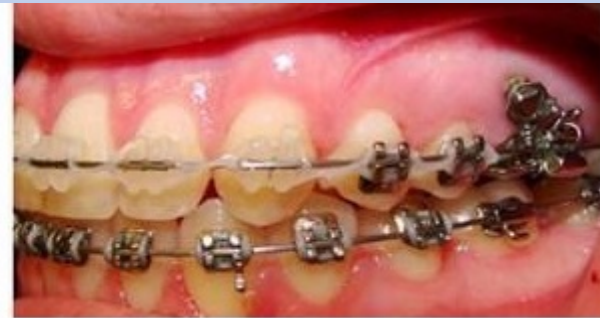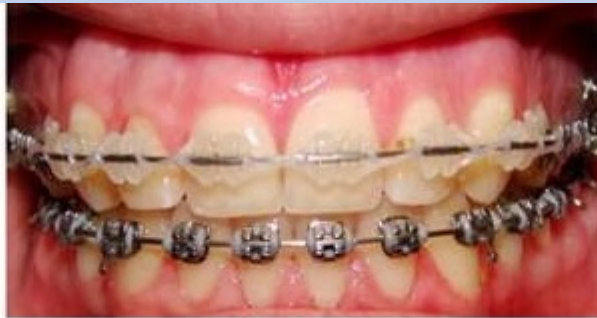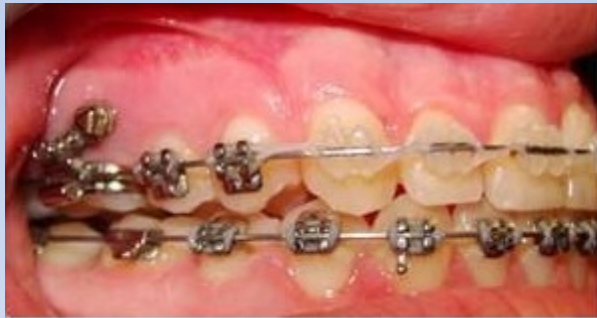- 15 years old -



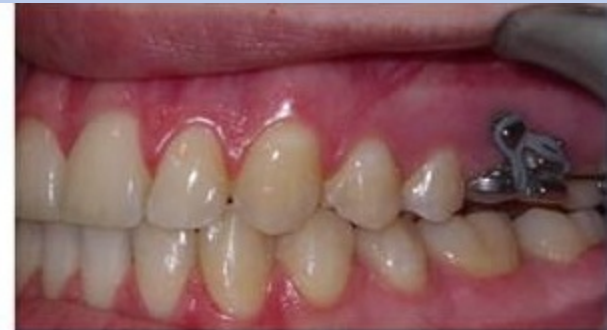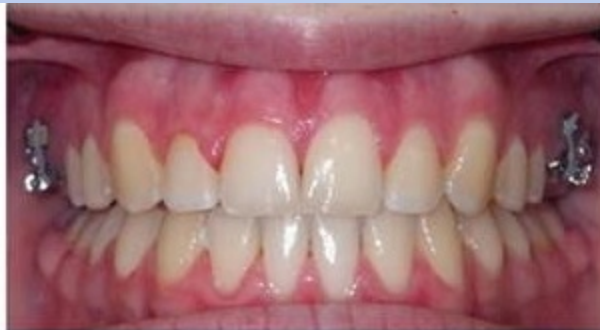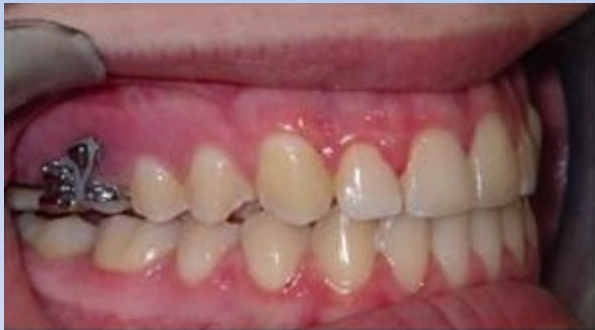“The Intruder” after 2 months



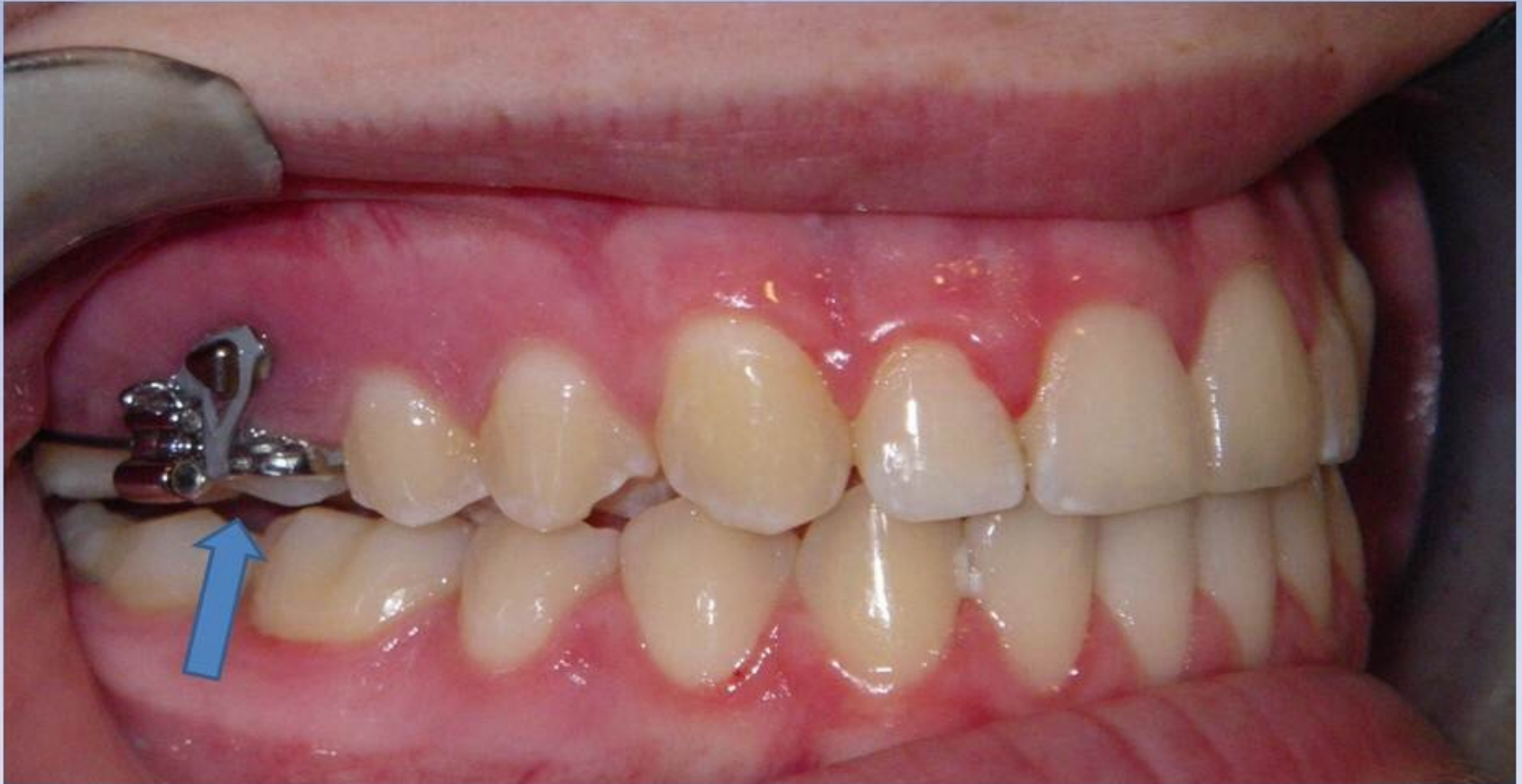“The Intruder” after 4 months



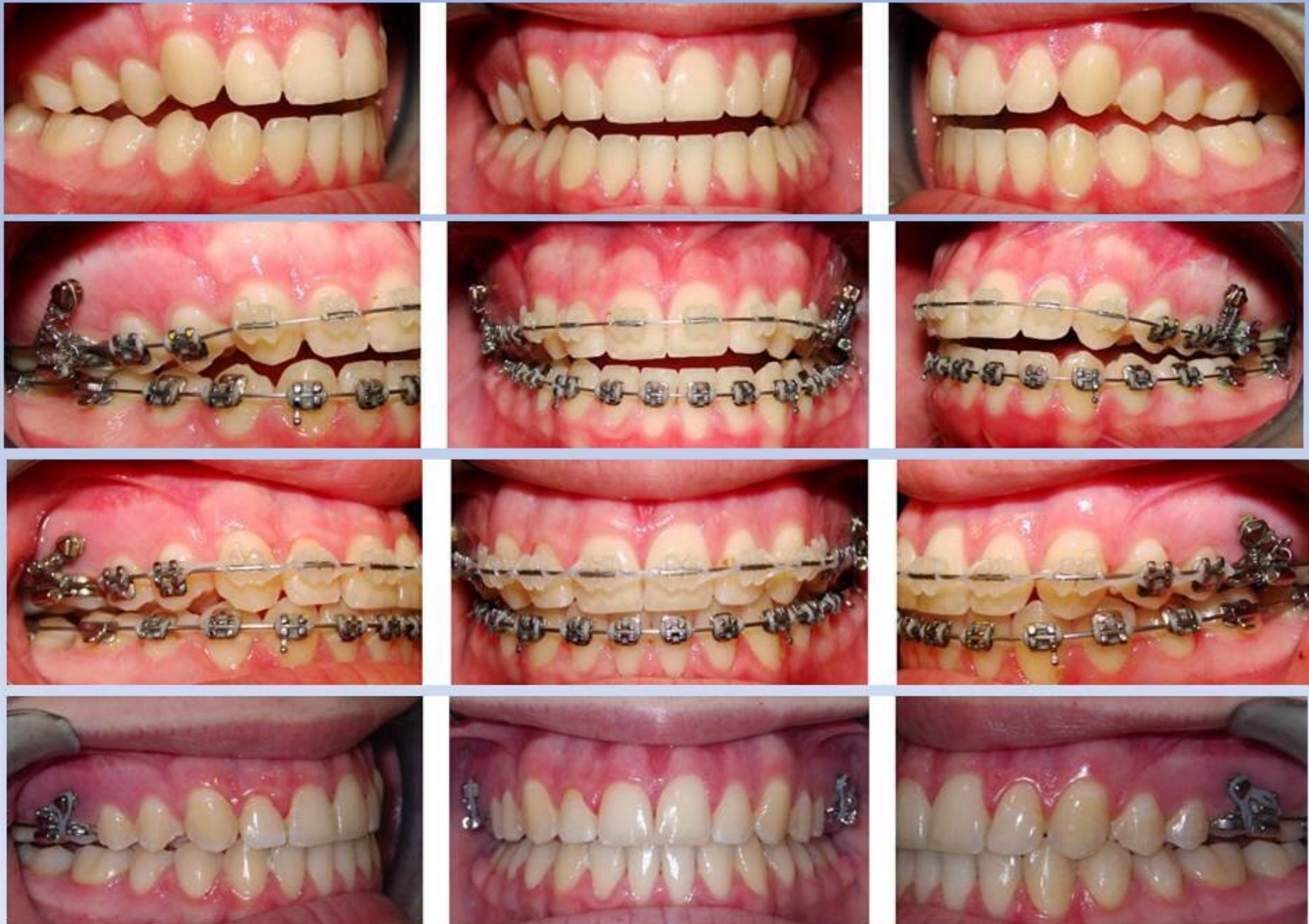Total Treatment Time – 6 months

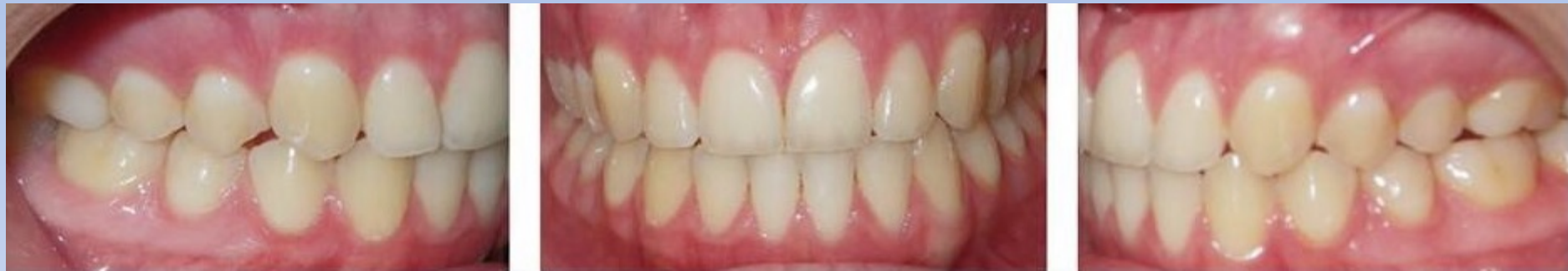

First and Second molars are out of occlusion



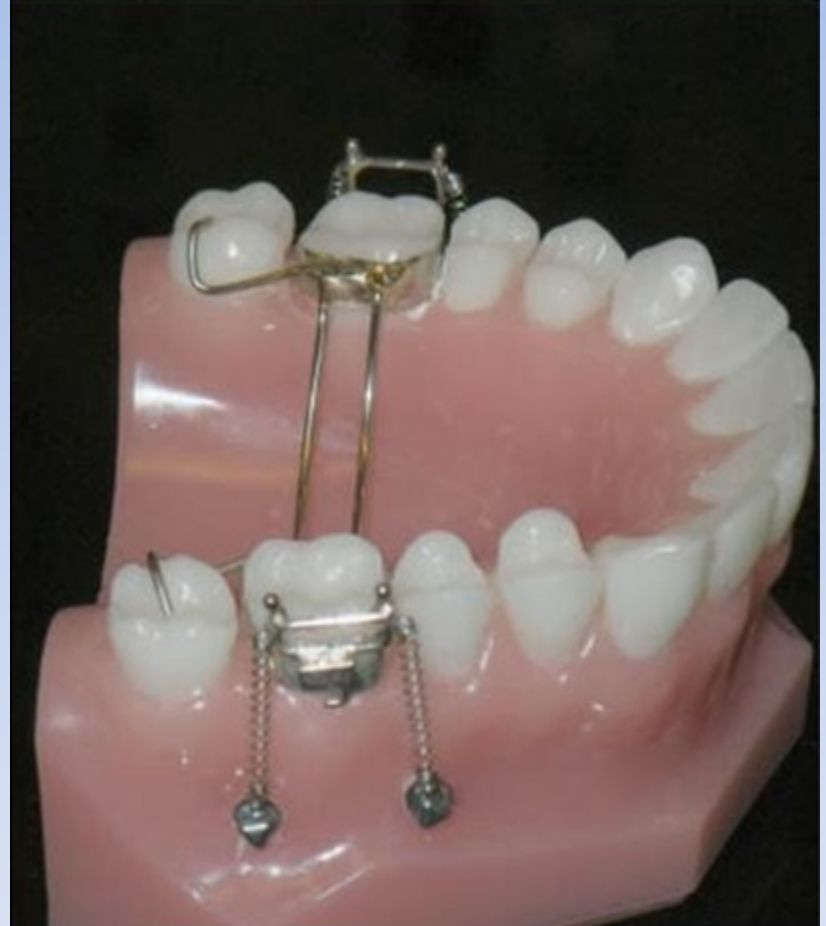6 months of treatment with Intruder






2 Years Post Treatment

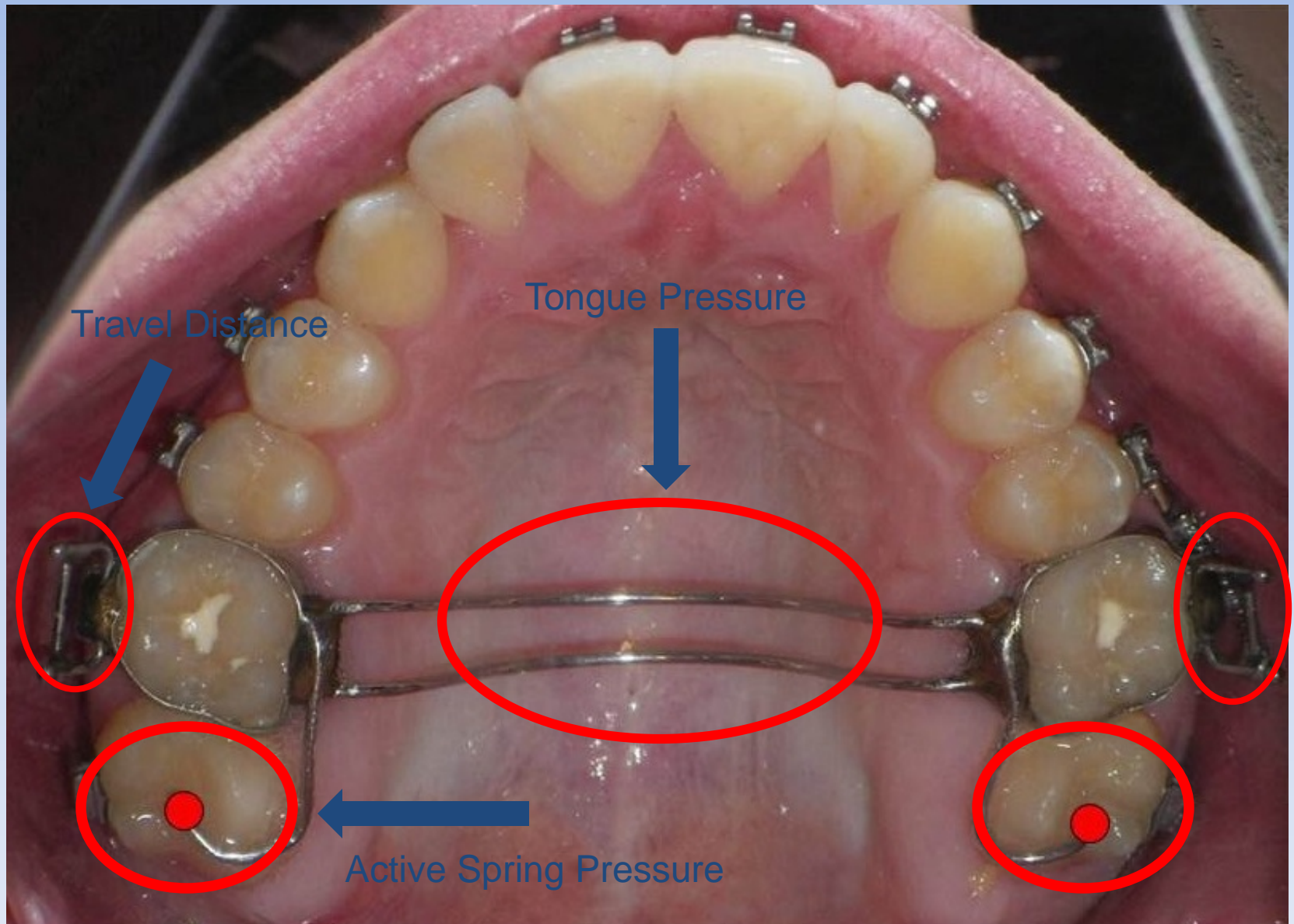
“The Intruder”



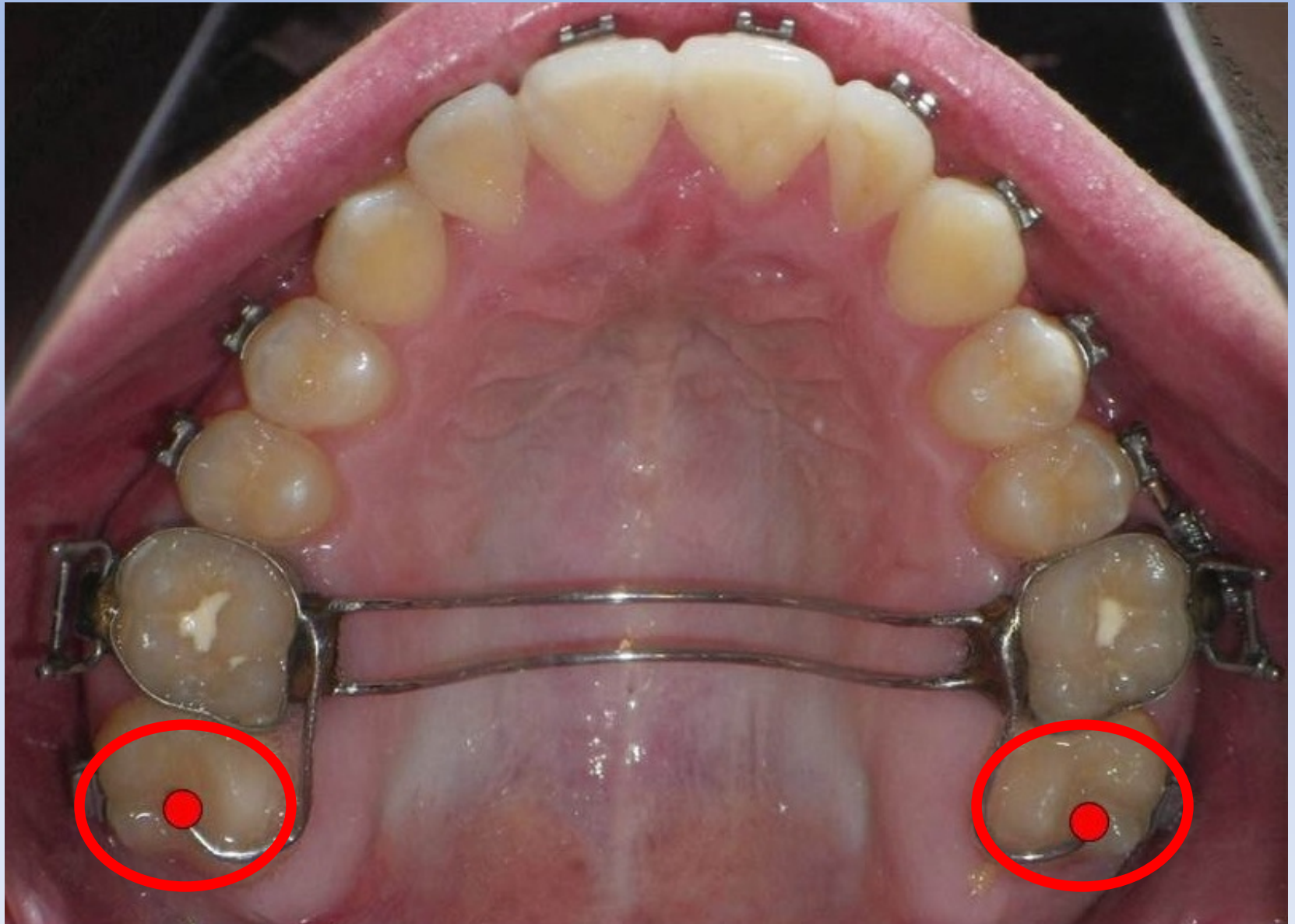
Three Main Features of “The Intruder”



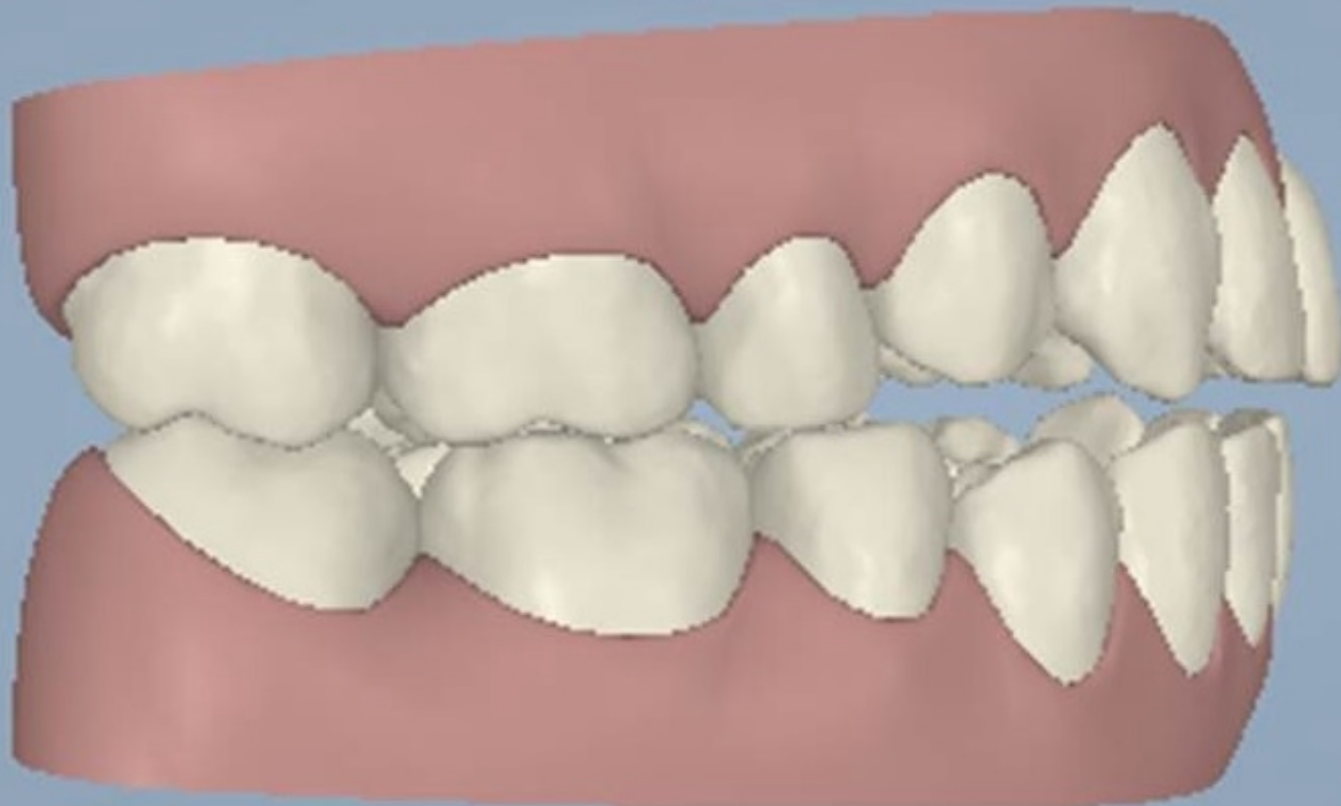
Three Main Features to “The Intruder”



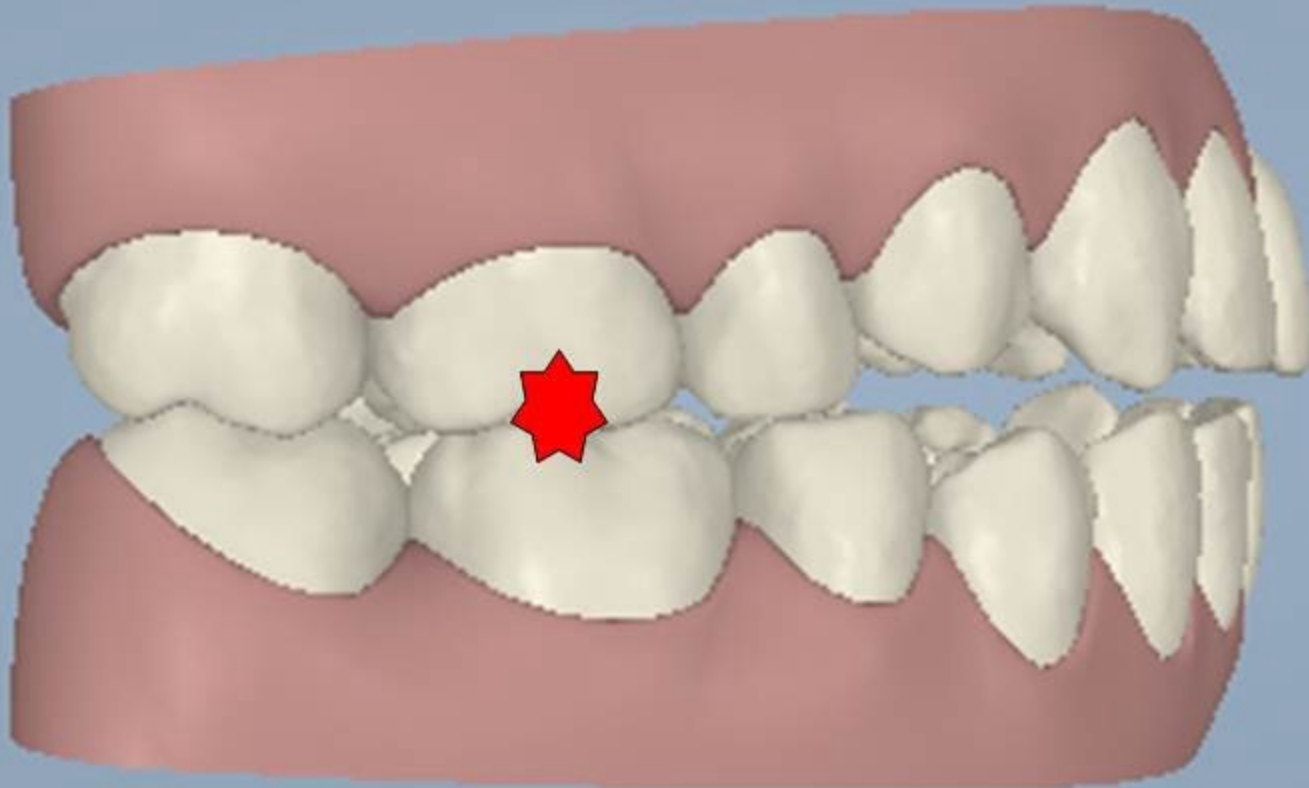
1 - Active Spring Pressure of the second molars



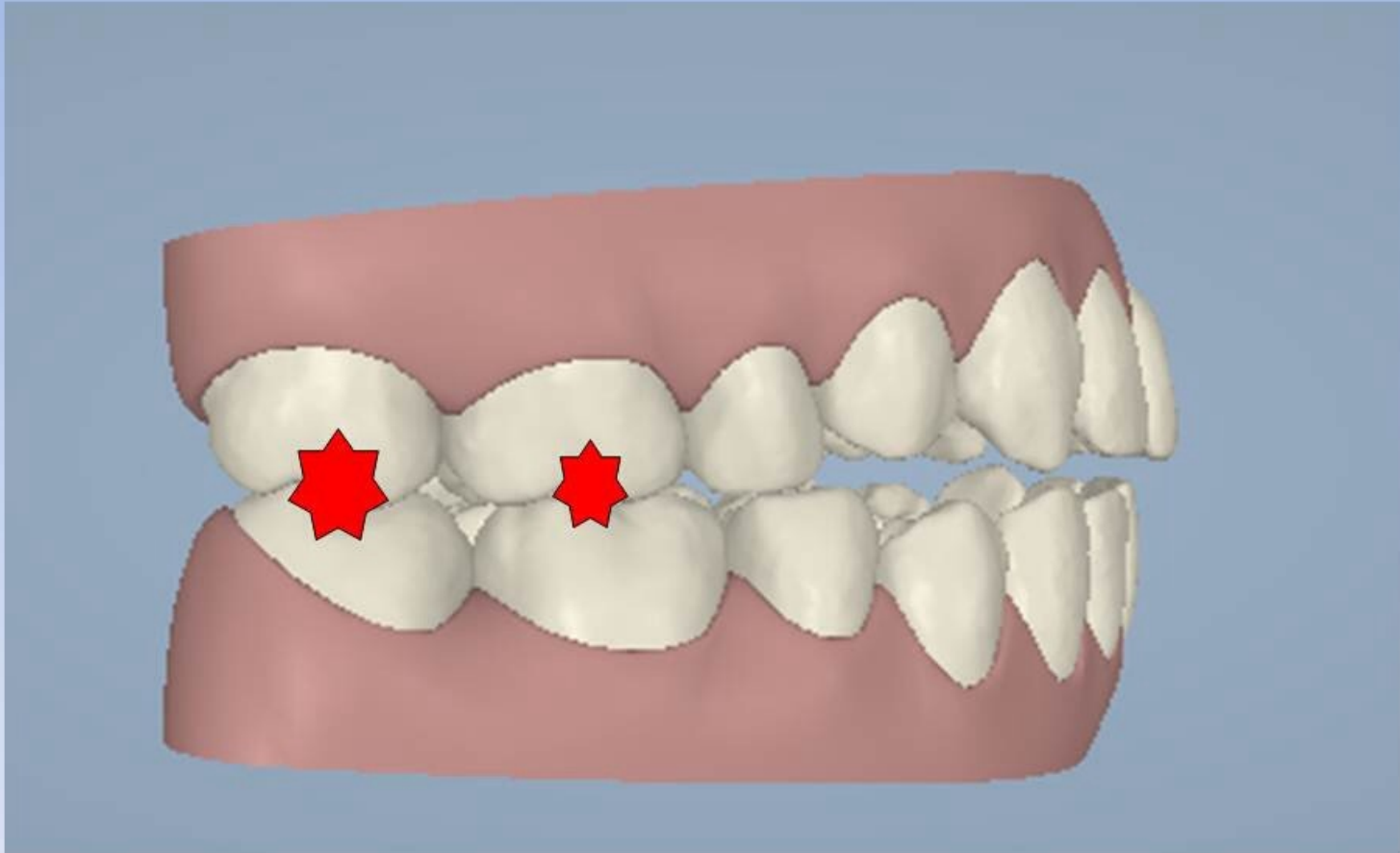
On Open Bite cases,
the occlusal contacts are mostly
on the first and second molars



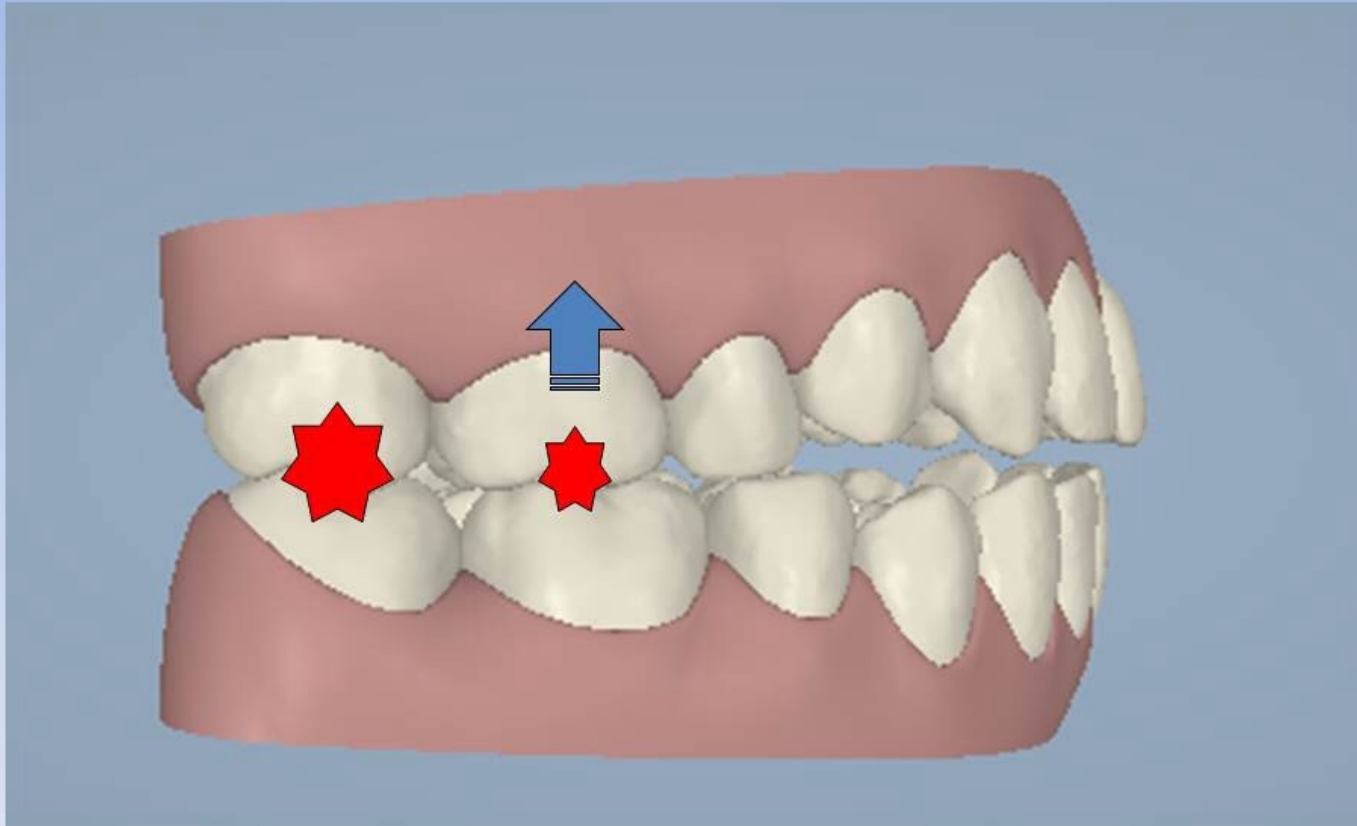
Usually moderate contact on the first molars



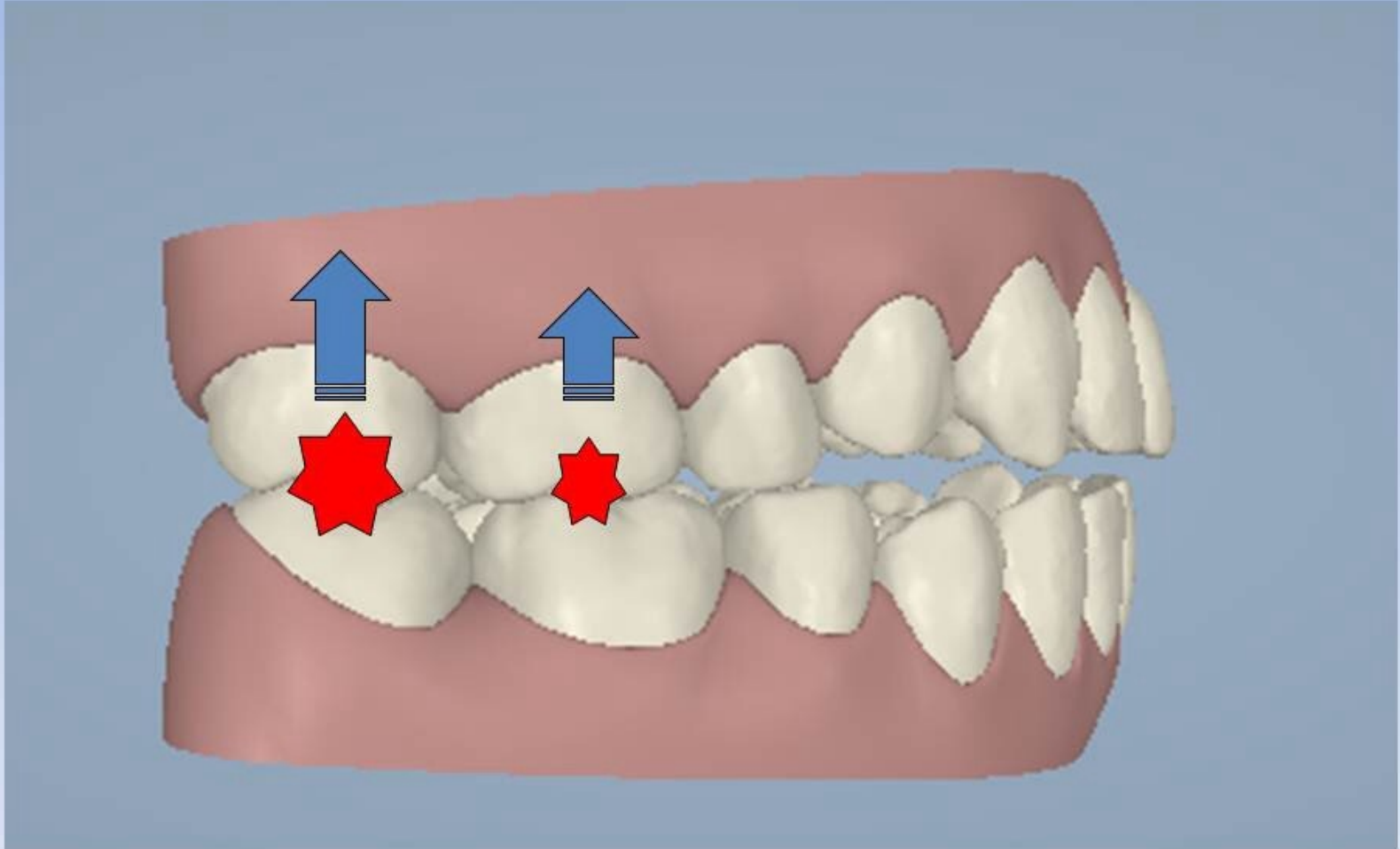
And heavier contact on the second molars



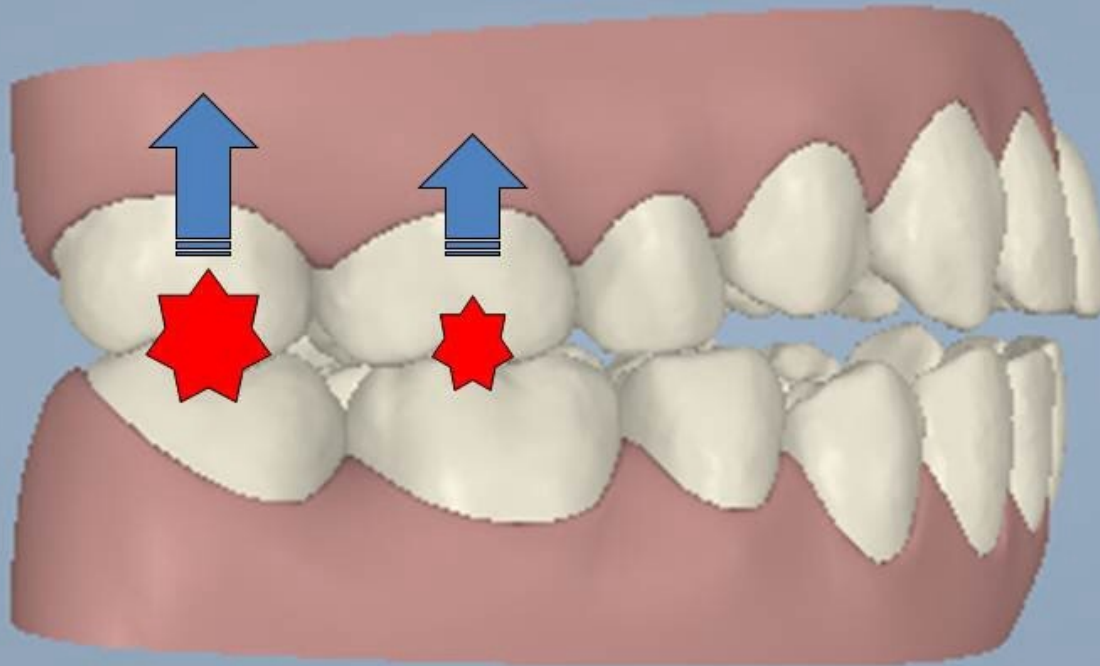
If you intrude your first molars 2 mm...



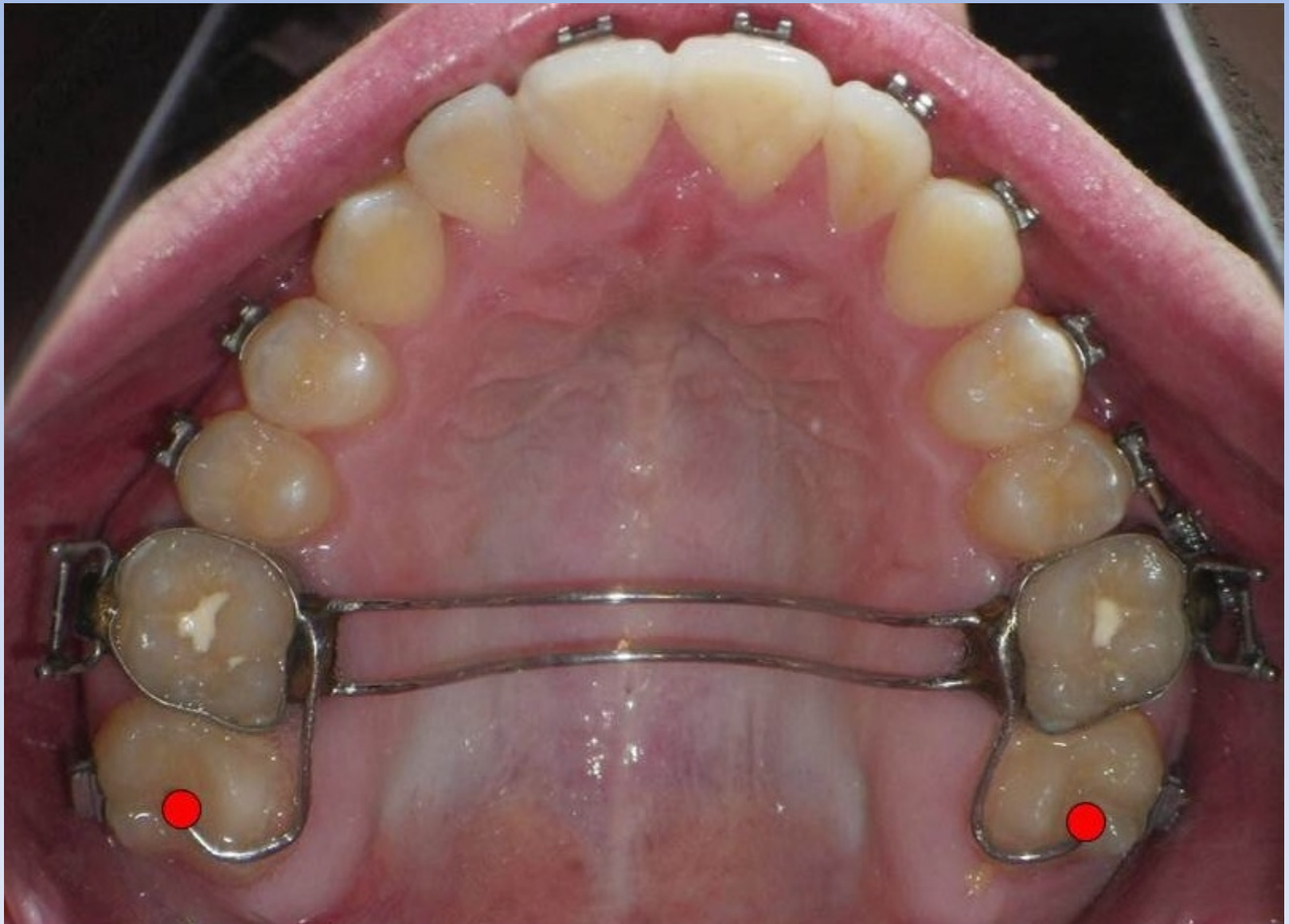You should intrude your second molars 3 mm.




The active occlusal spring will give you more intrusion of your second molars than the first



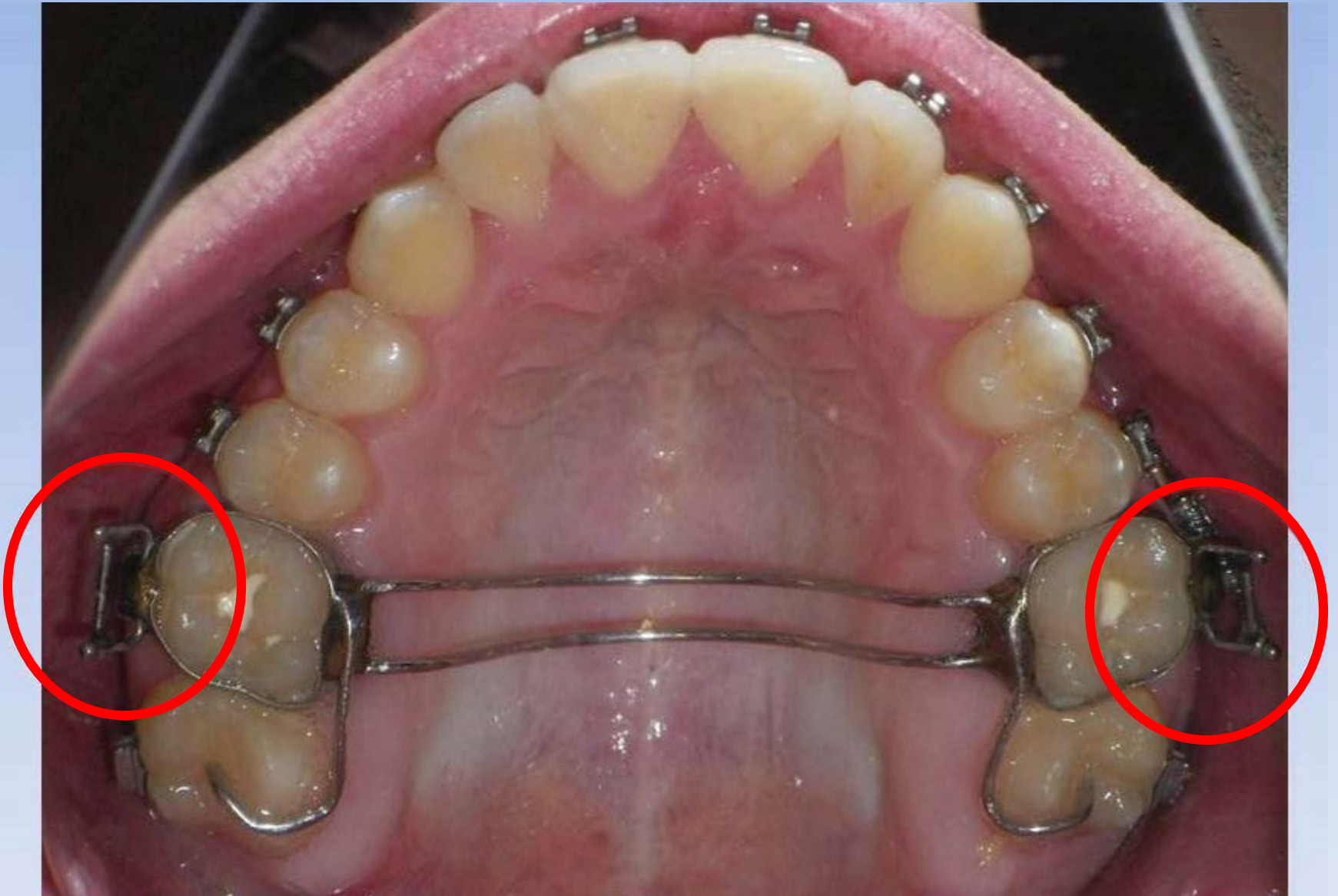
Active Spring Pressure of the Second Molars



2 – Increased Distance of Activation



2 – Increased Distance of Activation






Ball Clasp Extender

● Tad at Mucogingival Margin

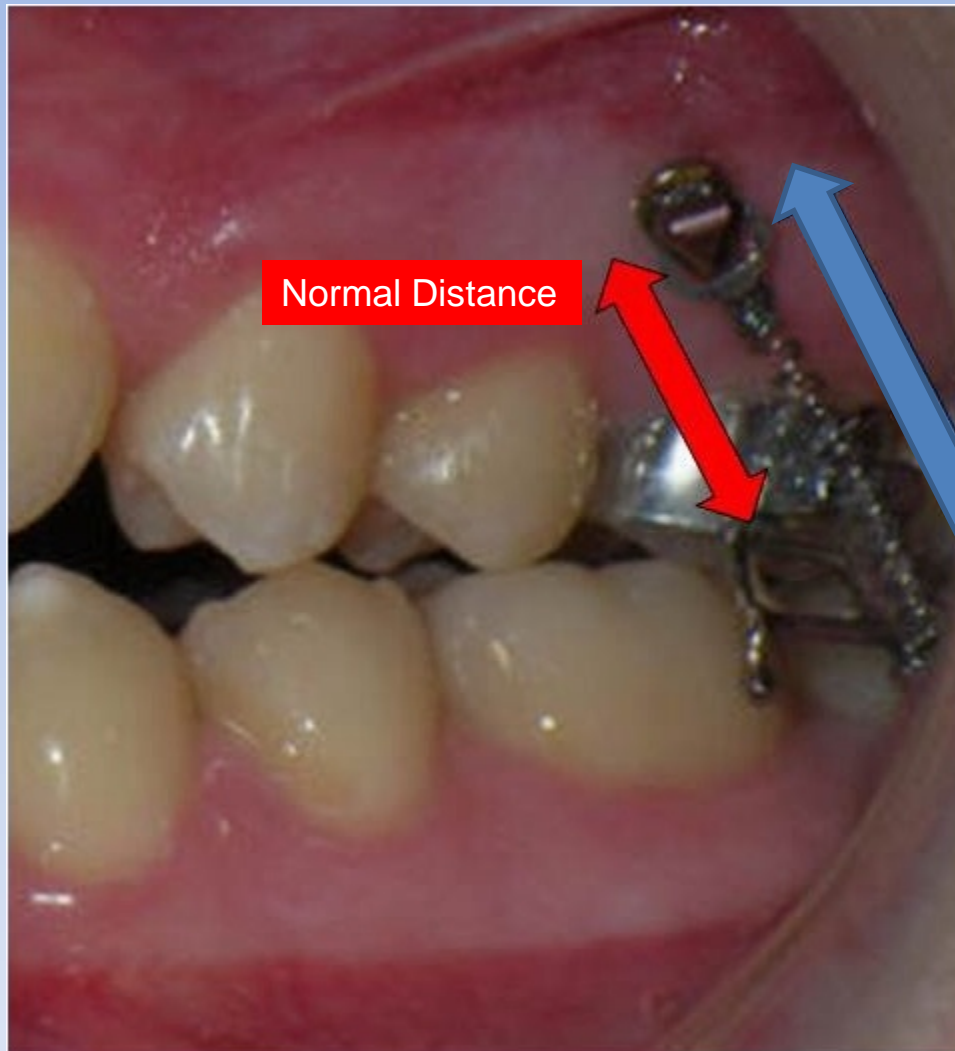




Normal distance of coil activation and intrusion



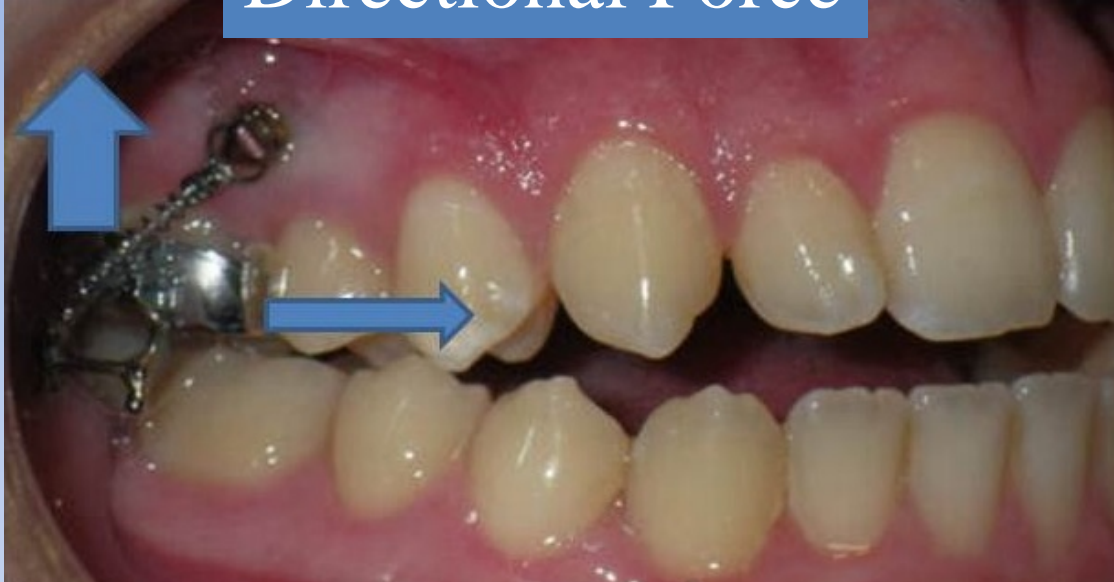Increased Distance



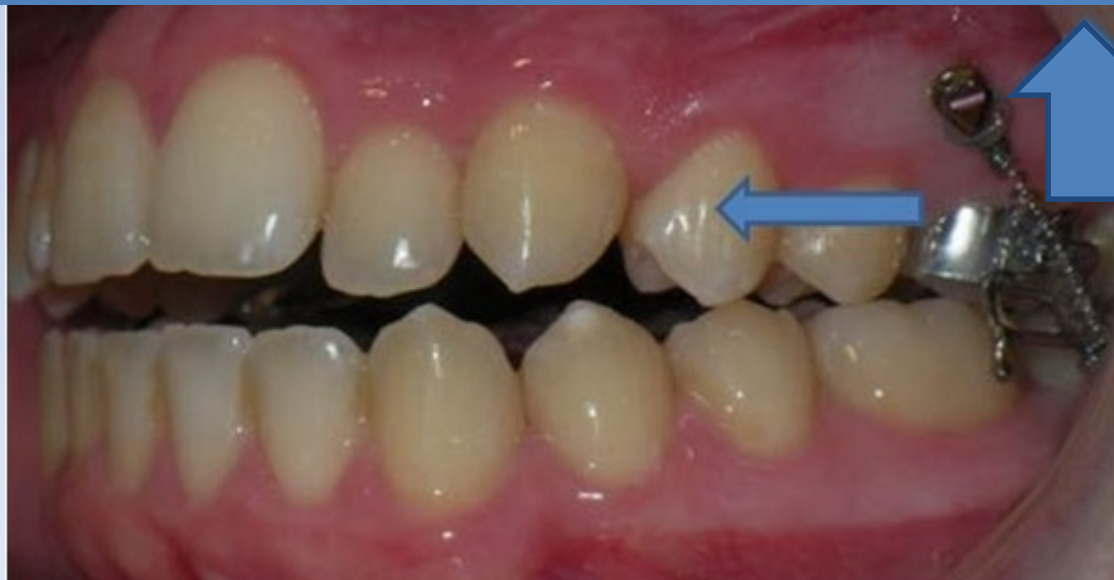Normal Distance

Increased distance
with extender


Directional Force

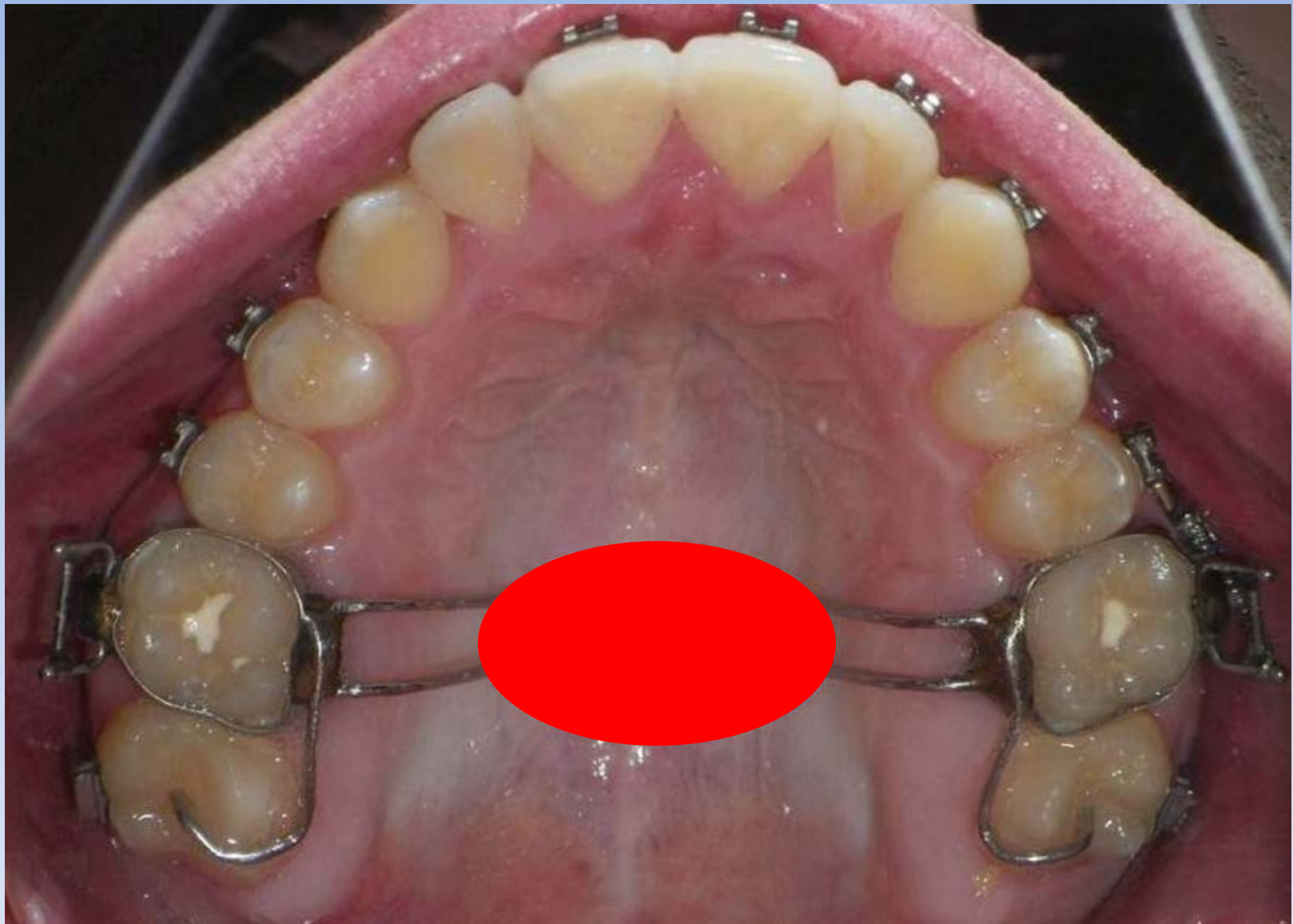


Adjust the direction of force for Class II or Class III cases

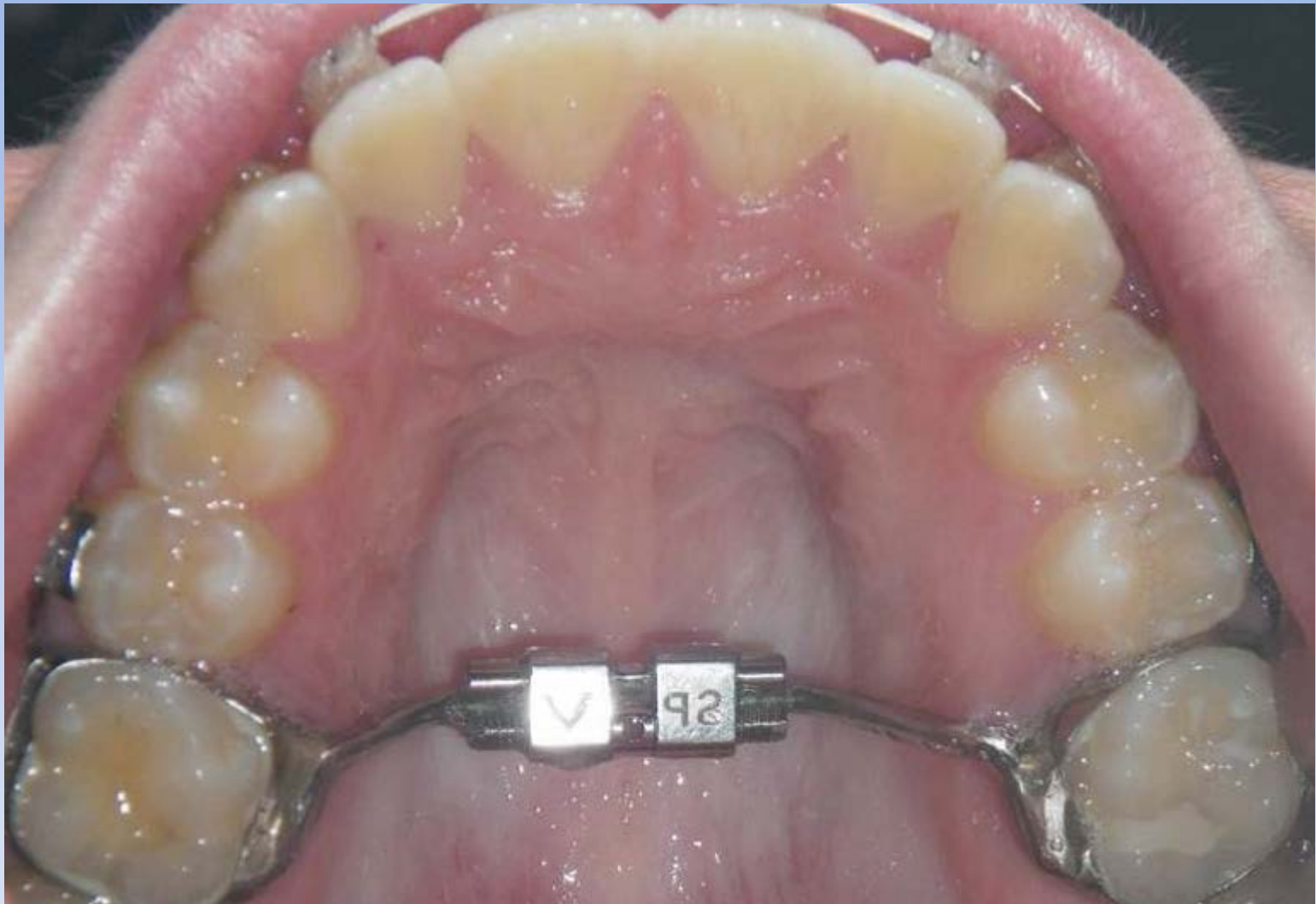

3 – Tongue Pressure to Assist with Intrusion

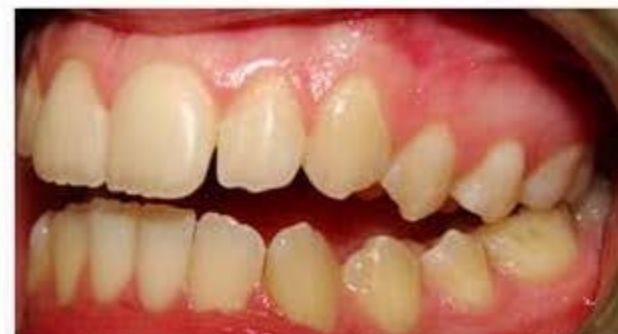
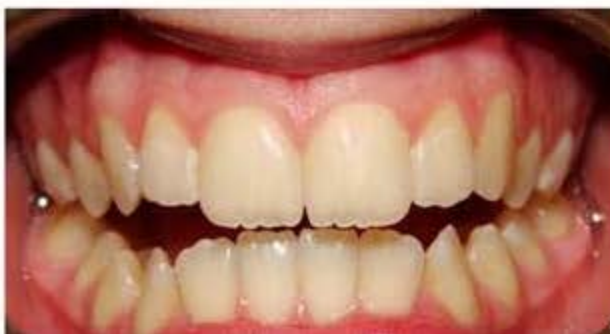
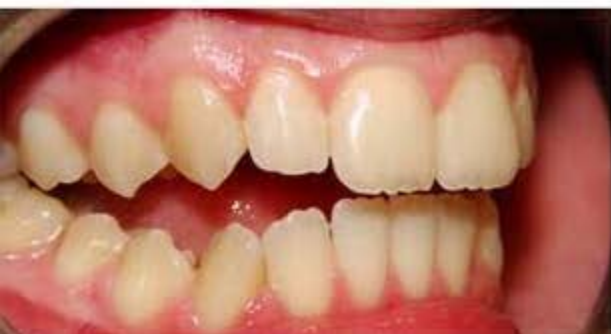
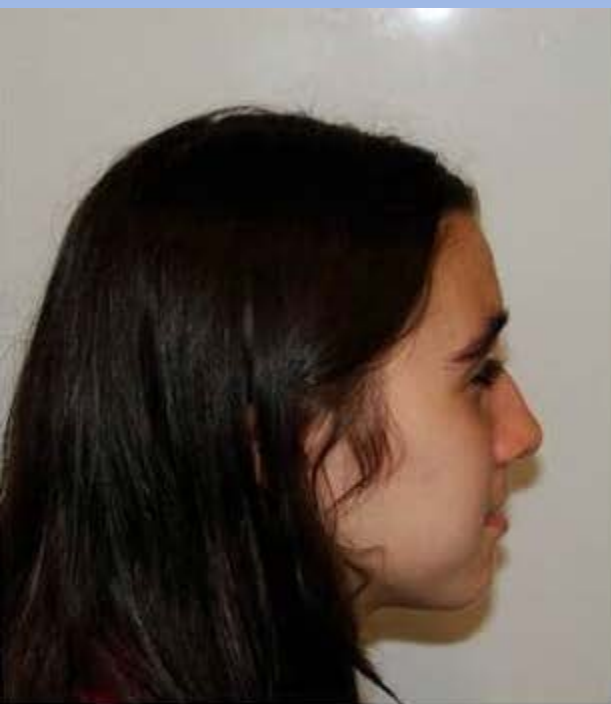
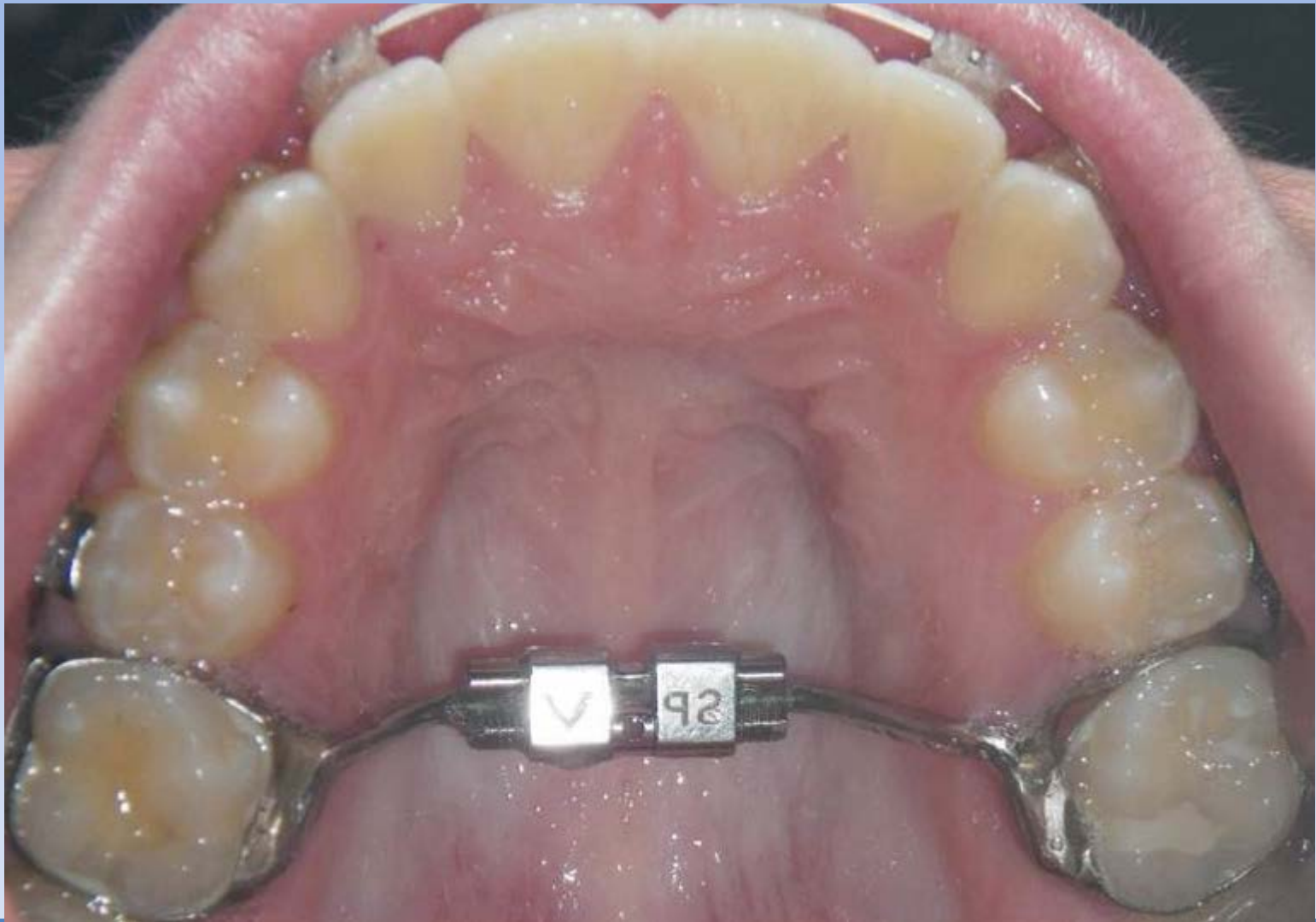Double Transpalatal Bar



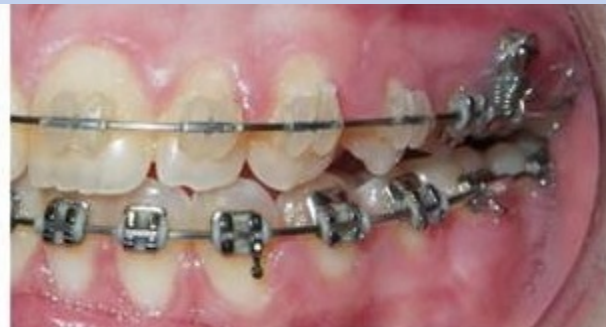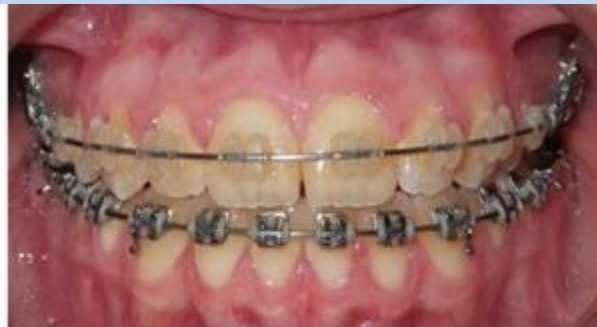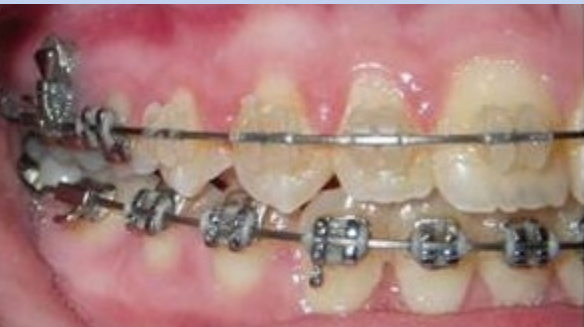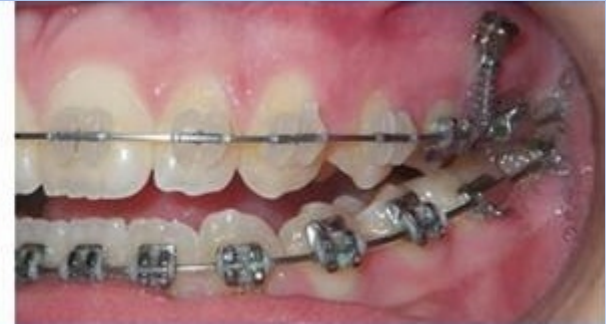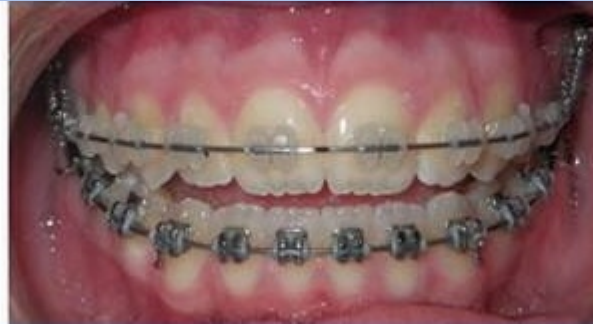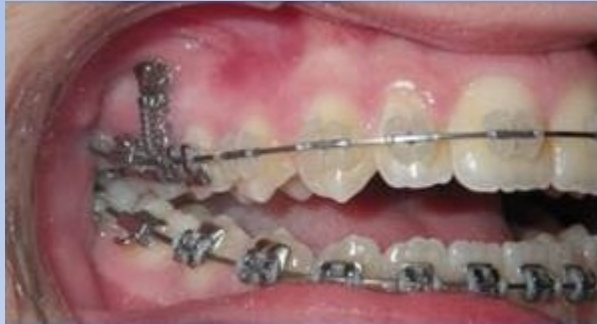or Mini FPA for Tongue Pressure AND Expansion



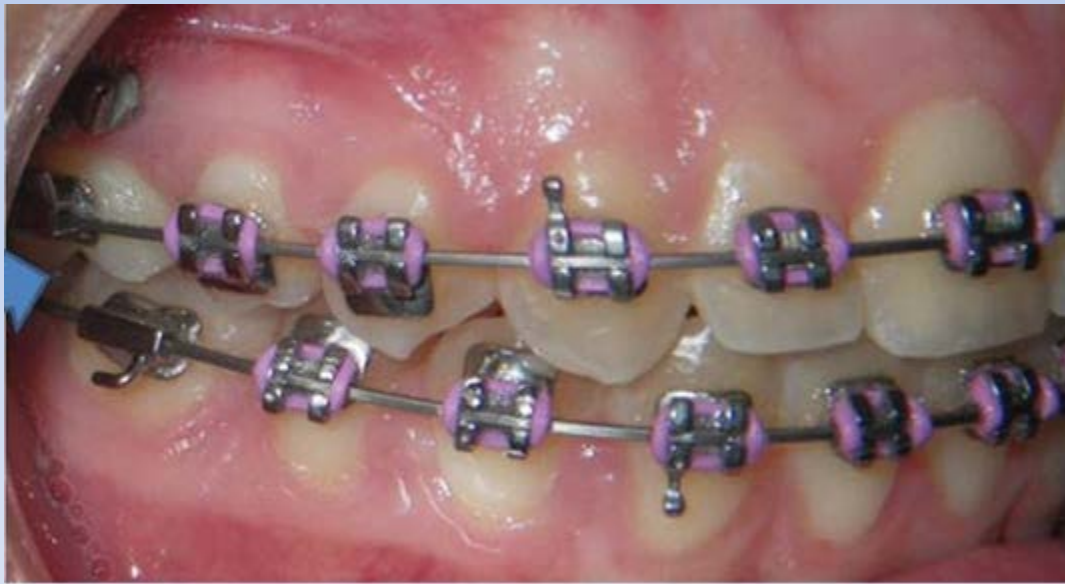
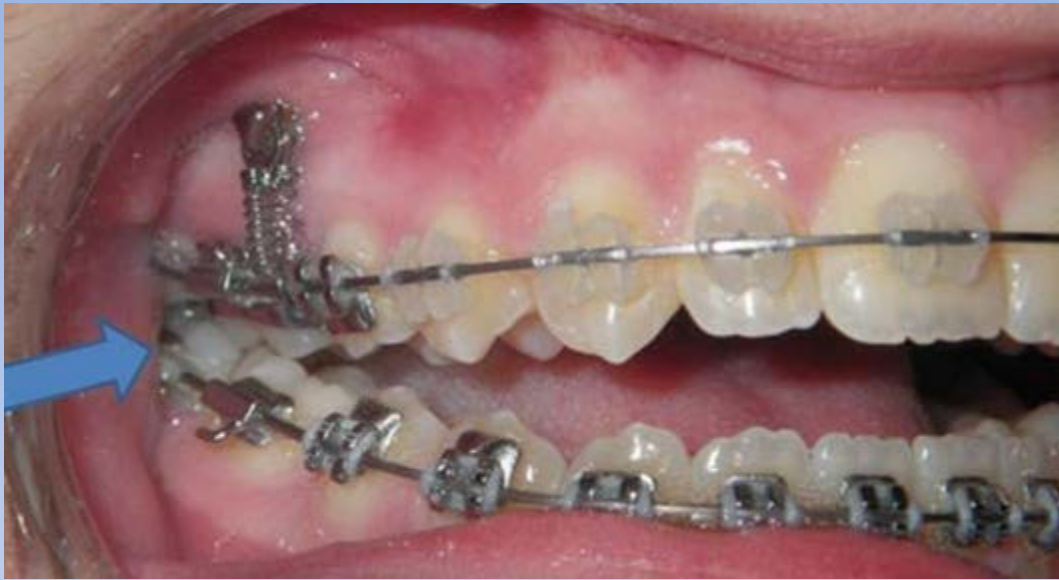Severe Vertical Excess and Maxillary Width Insufficiency
-13 year old -



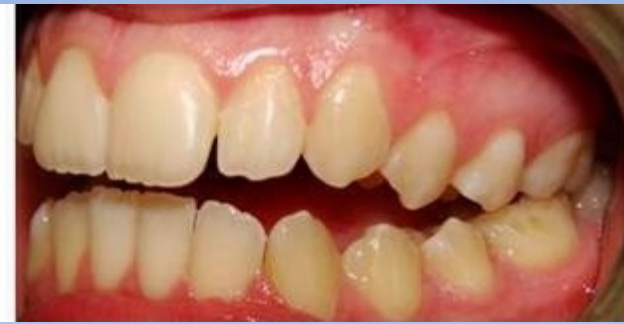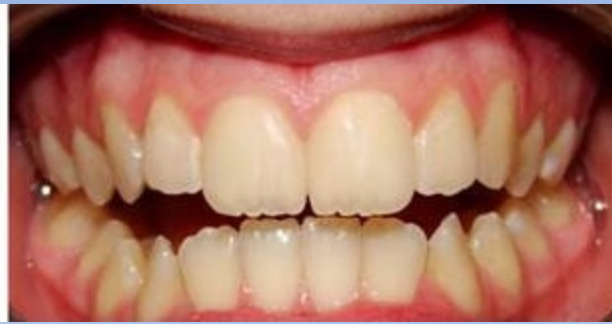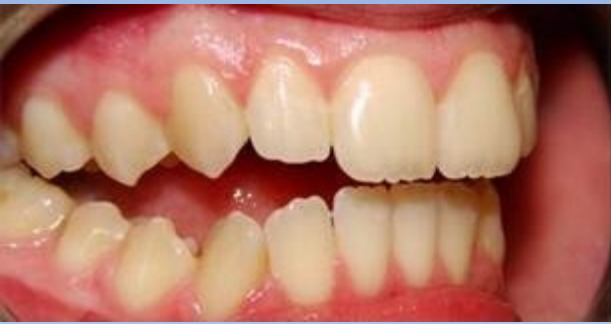Use Mini FPA when expansion is necessary with Intrusion



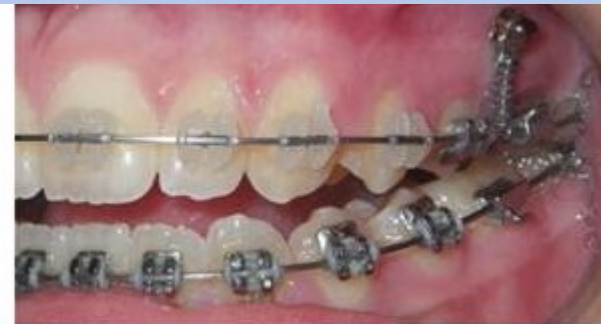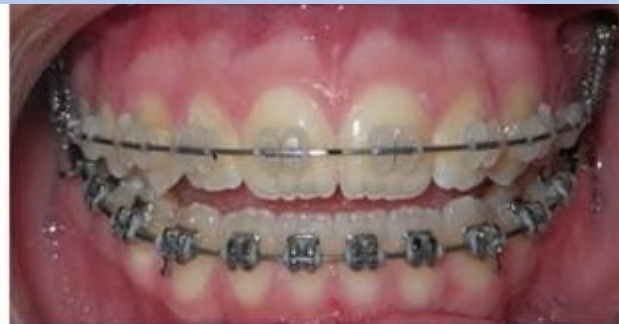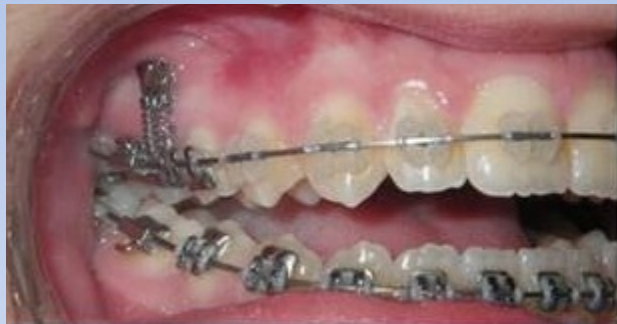7 months Treatment with the Intruder.
Bite is closed and posterior crossbites corrected



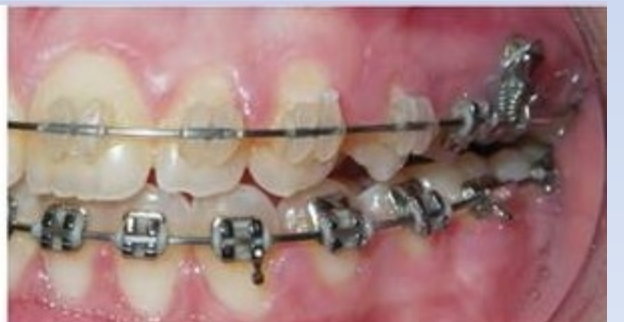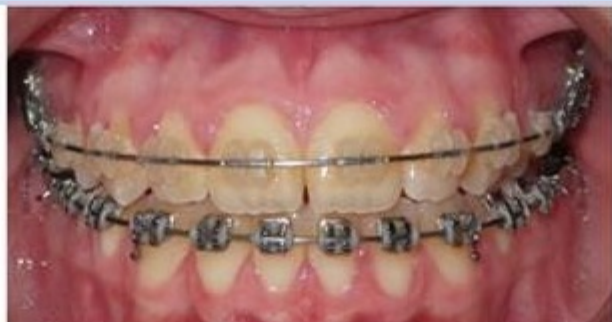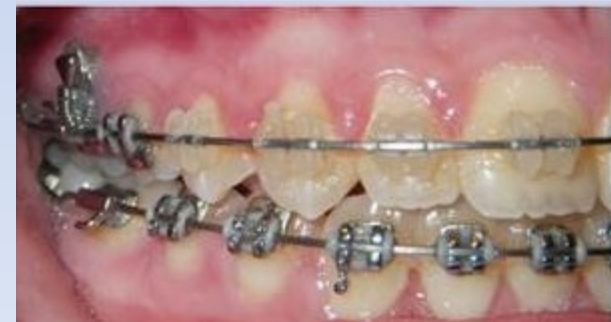Crossbite correction during intrusion



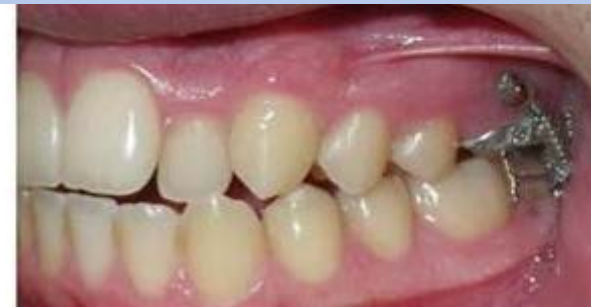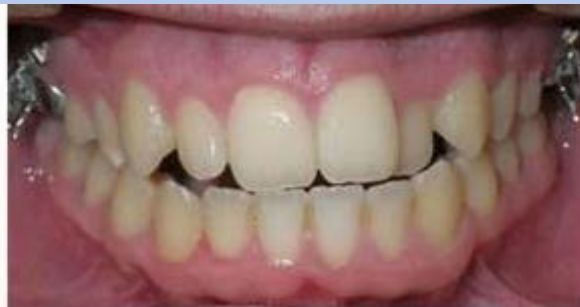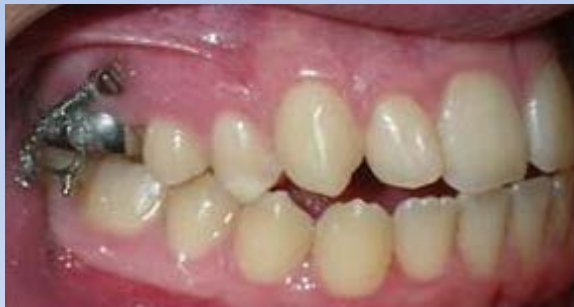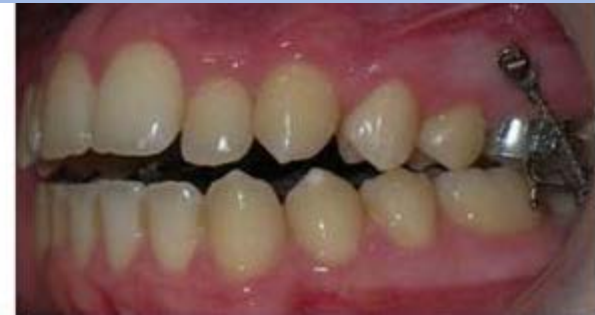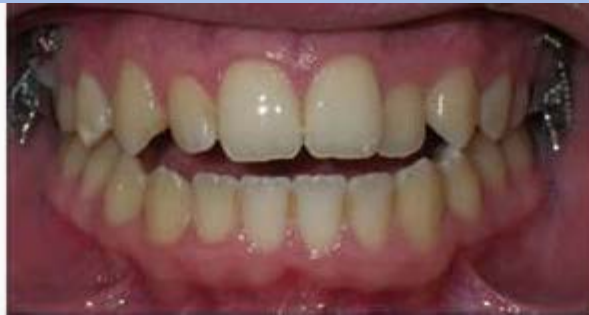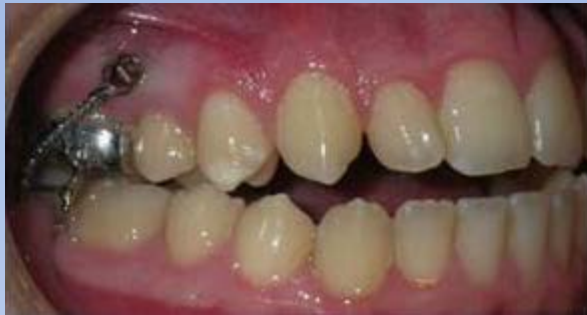3 months



7 months



3 Months of Treatment without Braces



“The Intruder”

